

Case report

## Emergency endovascular repair of ruptured visceral artery aneurysms

Umar Sadat\*, Nadim Noor, Tjun Tang and Kevin Varty

Address: Cambridge Vascular Unit, Addenbrooke's Hospital, Cambridge, UK

Email: Umar Sadat\* - sadat.umar@gmail.com; Nadim Noor - nadimnoor@doctors.org.uk; Tjun Tang - tt279@cam.ac.uk;

Kevin Varty - kevin.varty@addenbrookes.nhs.uk

\* Corresponding author

Published: 2 July 2007

Received: 23 February 2007

World Journal of Emergency Surgery 2007, 2:17 doi:10.1186/1749-7922-2-17

Accepted: 2 July 2007

This article is available from: <http://www.wjes.org/content/2/1/17>

© 2007 Sadat et al; licensee BioMed Central Ltd.

This is an Open Access article distributed under the terms of the Creative Commons Attribution License (<http://creativecommons.org/licenses/by/2.0>), which permits unrestricted use, distribution, and reproduction in any medium, provided the original work is properly cited.

### Abstract

**Background:** Visceral artery aneurysms although rare, have very high mortality if they rupture.

**Case presentation:** An interesting case of a bleeding inferior pancreaticoduodenal artery aneurysm is reported in a young patient who presented with hypovolemic shock while being treated in the hospital after undergoing total knee replacement. Endovascular embolization was successfully employed to treat this patient, with early hospital discharge.

**Conclusion:** Prompt diagnosis and endovascular management of ruptured visceral aneurysms can decrease the associated mortality and morbidity.

### Background

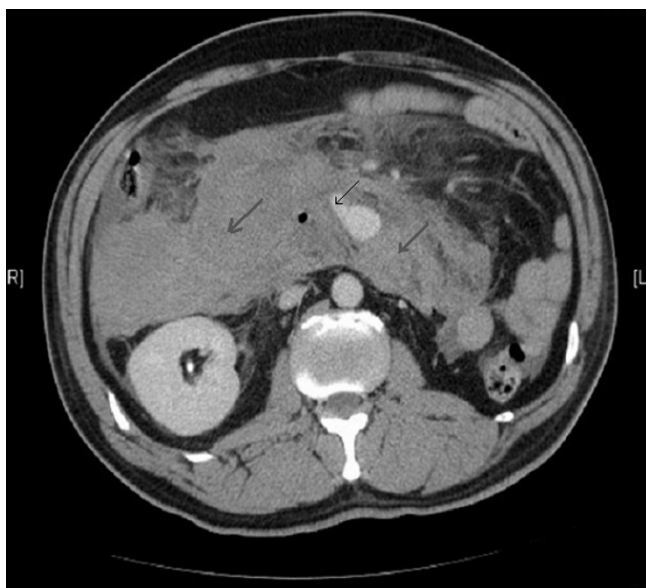
Visceral artery aneurysms are an uncommon pathology, with a potential for rupture. Splenic artery aneurysms (SAA) are the most common (60%), followed by hepatic (20%), superior mesenteric (5.9%) and tripod celiac (4%) artery aneurysms. An interesting case of a bleeding inferior pancreaticoduodenal artery aneurysm is presented and its management is also discussed.

### Case presentation

Two days following a unicompartmental knee replacement, a 46-year old man developed acute abdominal pain radiating to the back with nausea. He rapidly deteriorated with tachycardia, hypotension and abdominal distension. Blood tests revealed low haemoglobin of 7 g/dl. After haemodynamic stabilization with IV fluids and blood, a CT scan was performed which showed a massive intramesenteric bleed and an aneurysm arising from the pancreaticoduodenal arterial arcade (Figure 1). Past medical history was unremarkable.

Through a right-sided common femoral artery percutaneous cannulation, mesenteric arteriography was performed with the intention to perform coil embolisation. Images showed unusual distorted anatomy with a large and small gastroduodenal artery and an inferior pancreaticoduodenal artery running parallel. There was extravasation of contrast from an aneurysm arising from the small duodenal vessels close to the superior mesenteric artery (SMA) (Figure 2). The feeding vessels were selectively embolised with coils from both SMA and celiac axis and stasis of flow was achieved (Figure 3, 4).

The patient stayed in critical care unit for 5 days because of cardio respiratory compromise resulting from massive intramesenteric bleed pre-procedure with haemoglobin reaching 4 g/dl, stabilized by blood transfusion and also increased intrabdominal pressure that gradually returned back to normal. He was discharged from the hospital on 7th postoperative day.

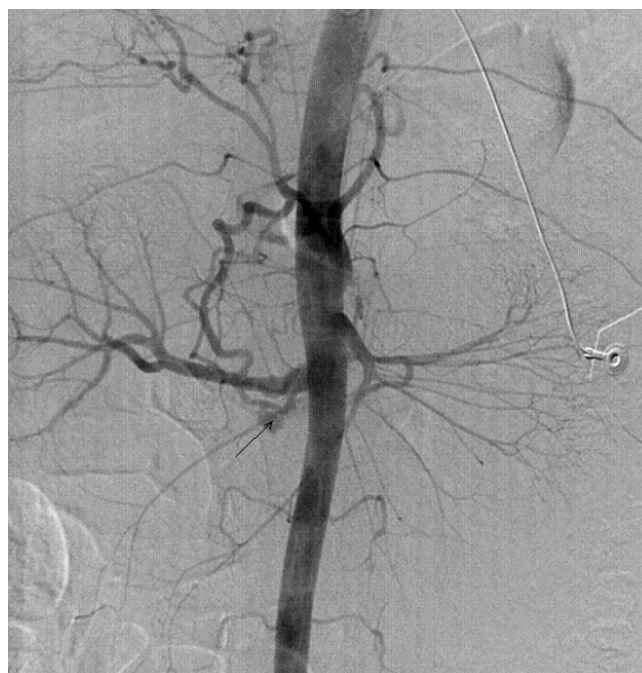

**Figure 1**  
Contrast enhanced CT scan showing leak from the inferior pancreaticoduodenal arterial arcade with intramesenteric bleed.

**Conclusion**

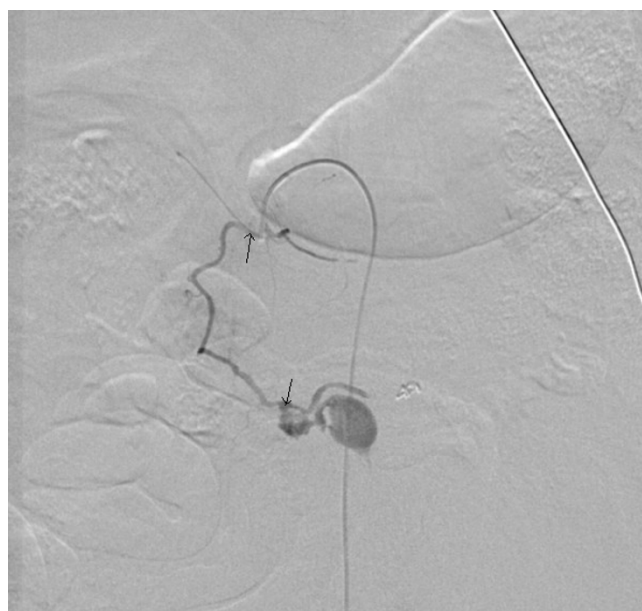Aneurysms of the pancreaticoduodenal artery are extremely rare entities – only about 1–2% of all visceral aneurysms. Although they may be present in the absence of any risk factors, as happened in our case, however nearly 30% of these aneurysms evolve as complications of acute or chronic pancreatitis [1], of which 10% occur in patients with chronic pancreatitis [2]. The enzymes released from the pancreatic pseudo cyst frequently involve the splenic artery (45%) followed by the gastroduodenal artery (17%) and then the pancreaticoduodenal artery (11%) [3]. Elastase can erode the artery wall leading to aneurysm formation [4]. When these aneurysms develop in the absence of pancreatitis, they are asymptomatic. Some are diagnosed as incidental findings on CT scans or arteriograms. If they present with acute retroperitoneal or intraperitoneal haemorrhage, as in this case, the reported mortality rates approach 20%.

These aneurysms can be managed surgically or by minimally invasive endovascular techniques with transcatheter embolization as done in this case or by a combination of both [5]. However, lately they have been successfully managed by thrombin injection [6,7] when tortuous anatomy makes embolization not feasible or using ethylene vinyl alcohol injection [8]. On extremely rare occasions they can thrombose on their own [9]. Surgical management is always challenging owing to the presence of multiple small pancreatic vessels that communicate with these aneurysms and may involve pancreatic resection. Mini-

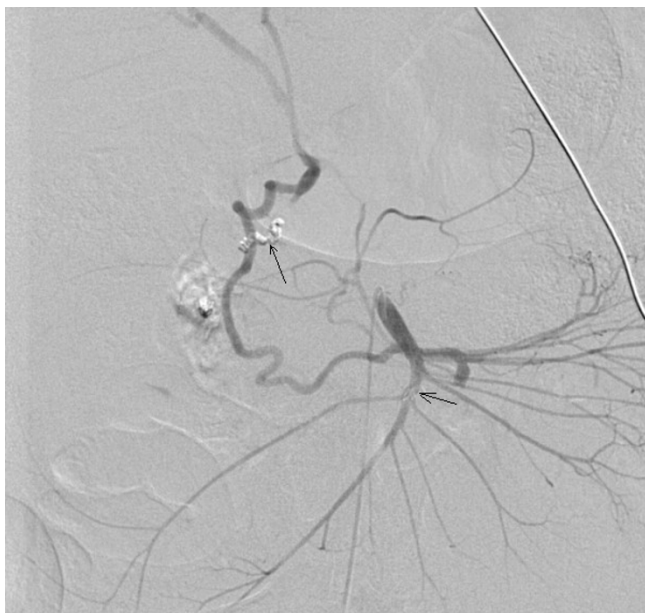

**Figure 2**  
Digital subtraction angiogram showing contrast leak from the ruptured aneurysm.

minally invasive coil embolization is therefore an attractive option and should be the first line of management, however it should be borne in mind that because in elective



**Figure 3**  
Coil embolization of feeding vessel through SMA.



**Figure 4**

Angiogram showing successful coils embolization of the feeding vessel through celiac axis with no residual leak from the aneurysm.

cases this approach has a 15% failure rate hence in a ruptured case this failure rate is likely to be higher.

#### Conflict of interests

The author(s) declare that they have no competing interests.

#### Authors' contributions

All the authors have been involved in literature search, writing and approval of final manuscript.

#### Acknowledgements

We would like to thank Dr D Appleton, Consultant Interventional radiologist, for his invaluable radiological expertise in treatment of this patient. Written consent was obtained from the patient or their relative for publication of case report.

#### References

1. Carr SC, Pearce WH, Vogelzang RL, McCarthy WJ, Nemcek AA, Yao JS: **Current management of visceral artery aneurysms.** *Surgery* 1996, **120**:627-633.
2. White AF, Baum S, Buranasiri S: **Aneurysms secondary to chronic pancreatitis.** *Am J Roentgenol* 1986, **127**:393-396.
3. Stabile BE, Wilson SE, Debas HT: **Reduced mortality from bleeding pseudocysts and pseudoaneurysms caused by pancreatitis.** *Arch Surg* 1983, **118**:45-51.
4. Bender JS, Levison MA: **Pseudoaneurysm of the gastroduodenal artery arising within a pancreatic pseudocyst.** *Ann Vasc Surg* 1992, **6**:171-172.
5. Teng W, Sarfati MR, Mueller MT, Kraiss LW: **A ruptured pancreaticoduodenal artery aneurysm repaired by combined endovascular and open techniques.** *Ann Vasc Surg* 2006, **20**(6):792-5.

6. Williams M, Alderson D, Virjee J, Callaway M: **CT-guided percutaneous thrombin injection for treatment of an inferior pancreaticoduodenal artery pseudoaneurysm.** *Cardiovasc Intervent Radiol* 2006, **29**(4):669-71.
7. Ghassemi A, Javit D, Dillon EH: **Thrombin injection of a pancreaticoduodenal artery pseudoaneurysm after failed attempts at transcatheter embolization.** *J Vasc Surg* 2006, **43**(3):618-22.
8. Bratby MJ, Lehmann ED, Bottomley J, Kessel DO, Nicholson AA, McPherson SJ, Morgan RA, Belli AM: **Endovascular embolization of visceral artery aneurysms with ethylene-vinyl alcohol (Onyx): a case series.** *Cardiovasc Intervent Radiol* 2006, **29**(6):1125-8.
9. Lois JF, Falchuk KH, Peterson LM, Harrington DP: **Spontaneous obliteration of pancreaticoduodenal artery aneurysm after retroperitoneal hemorrhage.** *Cardiovasc Intervent Radiol* 1983, **6**:47-50.

Publish with **BioMed Central** and every scientist can read your work free of charge

"BioMed Central will be the most significant development for disseminating the results of biomedical research in our lifetime."

Sir Paul Nurse, Cancer Research UK

Your research papers will be:

- available free of charge to the entire biomedical community
- peer reviewed and published immediately upon acceptance
- cited in PubMed and archived on PubMed Central
- yours — you keep the copyright

Submit your manuscript here:  
[http://www.biomedcentral.com/info/publishing\\_adv.asp](http://www.biomedcentral.com/info/publishing_adv.asp)

