

Case report

Open Access

Ileo-anal pouch necrosis secondary to small bowel volvulus: A case report

Sandeep Patel*, Gurcharan Salotera, Shashank Gurjar, Jim Hewes, Ibrahim Ahmed and Brian Andrews

Address: Department of Surgery, Medway Maritime Hospital, Gillingham, Kent, UK

Email: Sandeep Patel* - sandeep99@doctors.net.uk; Gurcharan Salotera - gssalotera@doctors.org.uk; Shashank Gurjar - svgurjar@gmail.com; Jim Hewes - jimhewes@hotmail.com; Ibrahim Ahmed - iahmed@medway.nhs.uk; Brian Andrews - b.andrews@medway.nhs.uk

* Corresponding author

Published: 30 May 2008

Received: 12 February 2008

World Journal of Emergency Surgery 2008, 3:18 doi:10.1186/1749-7922-3-18

Accepted: 30 May 2008

This article is available from: <http://www.wjes.org/content/3/1/18>

© 2008 Patel et al; licensee BioMed Central Ltd.

This is an Open Access article distributed under the terms of the Creative Commons Attribution License (<http://creativecommons.org/licenses/by/2.0>), which permits unrestricted use, distribution, and reproduction in any medium, provided the original work is properly cited.

Abstract

Introduction: Small bowel volvulus is a rare occurrence in the Western world and its occurrence after ileo-anal pouch formation is even rarer.

Case Presentation: We report a case of a 26 year old lady who presented with small bowel volvulus and subsequent ischaemia and necrosis of her ileo-anal pouch created 5 years previously.

Conclusion: This case illustrates a rare but potentially devastating complication of ileo-anal pouch formation and as such the diagnosis should be borne in mind when a patient with a pouch presents with an acute abdomen.

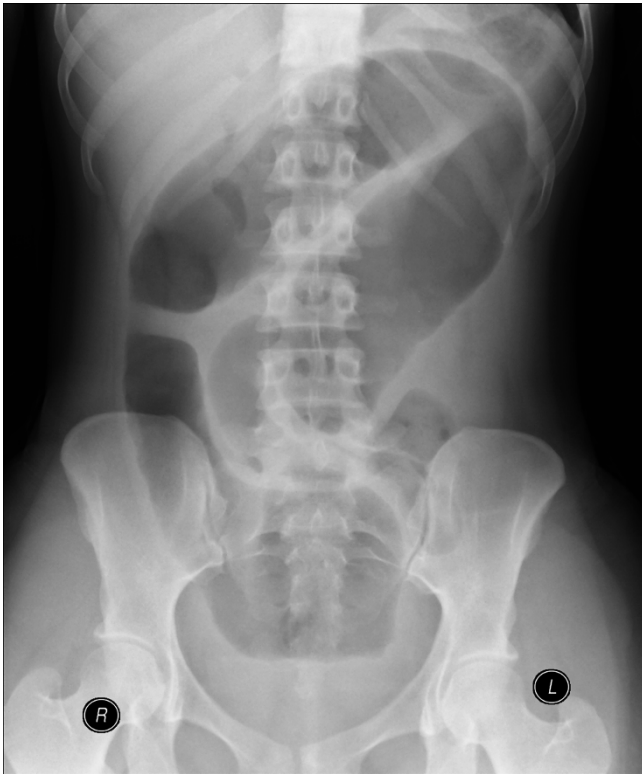
Introduction

Small bowel volvulus (SBV) as a cause of intestinal obstruction is an uncommon surgical emergency. It is a recognised entity in neonates associated with abnormal midgut rotation[1,2], but is seldom seen in adults. Delayed diagnosis may lead to bowel ischaemia, infarction and consequent morbidity. We describe a case of acute small bowel volvulus and resultant pouch necrosis in a patient who had previously undergone total colectomy with ileo-anal pouch formation.

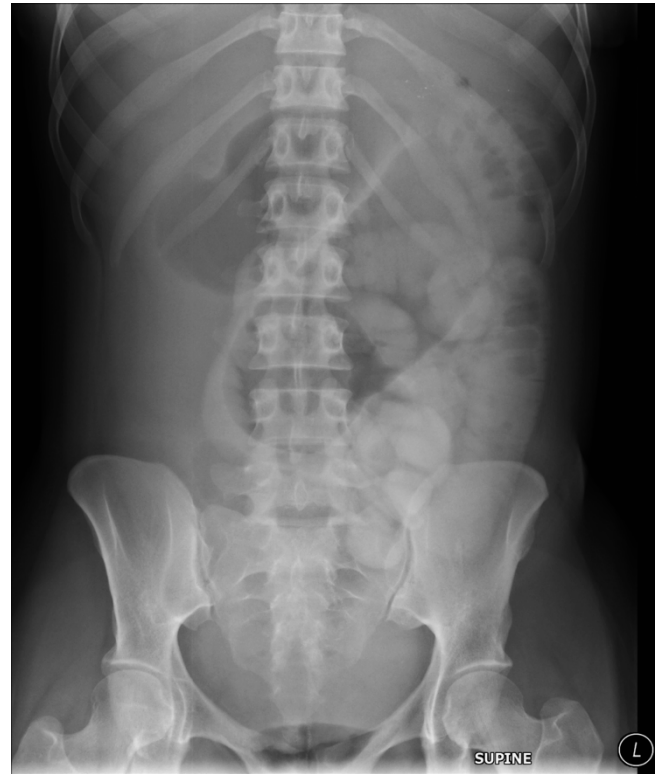
Case Report

A 26-year old Afro-Caribbean lady presented acutely with a 24-hour history of colicky abdominal pain, fever and vomiting. She was known to have sickle cell trait and a history of ulcerative colitis, for which she had undergone a total colectomy with ileo-anal pouch formation 5 years earlier. On examination she had a distended abdomen,

generalised abdominal tenderness and features suggestive of small bowel obstruction. The clinical diagnosis was confirmed on plain and contrast radiography (Figure 1, 2). An abdominal CT scan demonstrated a dilated proximal jejunum with closed loop obstruction of the terminal ileum and a positive 'corkscrew' sign (Figure 3). Therapeutic oral gastrografin was tried but failed. The patient deteriorated and proceeded to laparotomy. At surgery a section of small bowel proximal to the pouch was found to have twisted on its mesentery. This small bowel volvulus had caused a closed loop obstruction with consequent necrosis of both the section of twisted jejunum and the ileo-anal pouch (Figure 4, 5). The pouch was taken down and the sections of gangrenous bowel excised, and an end ileostomy fashioned. Histological analysis of the excised specimens confirmed the operative findings of small bowel gangrene. The patient made a slow post-operative

**Figure 1**

A loop of dilated small bowel mid abdomen with no clear valvulae conniventes continuing into the pelvis.

**Figure 2**

A six film hour post therapeutic gastrograffin consistent with mechanical small bowel obstruction.

recovery as a consequence of malabsorption secondary to short bowel syndrome.

Discussion

SBV is a rare cause of small bowel obstruction in the West with a reported incidence of 1.7–5.7 cases per 100,000 habitants[1] and an associated mortality rate of upto 35%[3]. Primary SBV occurs when the small bowel rotates around its mesentery (in the absence of congenital or adhesive bands) causing interruption to the blood supply to and from the bowel resulting in venous congestion, obstruction, ischaemia and eventual necrosis. Various aetiological factors have been proposed in its development as a primary condition including diet and changes in gut motility[4]. Observational studies have noted an increased incidence of the condition during periods of feasting in the Third World where after starvation large amounts of food are rapidly ingested[5]. The displacement of the jejunum into the pelvis by a large food bolus may cause the empty small bowel to move proximally within the abdomen and cause volvulus. This requires the presence of a short and broad mesentery and firm abdominal wall muscles to prevent coronal movement of the bowel[6].

Changes in gut motility and tone have also been implicated in the formation of primary volvulus. Chaussade *et al* reported the presence of increased discrete clustered contractions after small bowel anastomosis to the anal sphincter, possibly as a consequence of functional obstruction[7]. Alterations in the levels of the gut motility stimulant 5-hydroxy-tryptamine (5-HT), as well as diabetic autonomic neuropathy have also been implicated[8,9].

Secondary SBV is more commonly seen in the West and can develop as a result of twisting of the small bowel around a fixed point that may have arisen due to adhesions[10], internal herniation [11], or Meckel's diverticulum[12]. An association between SBV and large small bowel diverticula (>3 cm) has also been noted [13] as well as an isolated report of SBV secondary to a migrating mesh plug[14]. The alteration of the relationship of the superior mesenteric artery to its corresponding vein, as a result of torsion of the mesentery around its attachment, and the associated 'swirl sign' are important markers of SBV[15].

Ileo-anal pouch formation is a commonly performed procedure for patients with ulcerative colitis to maintain faecal continence following colectomy. Complications of the

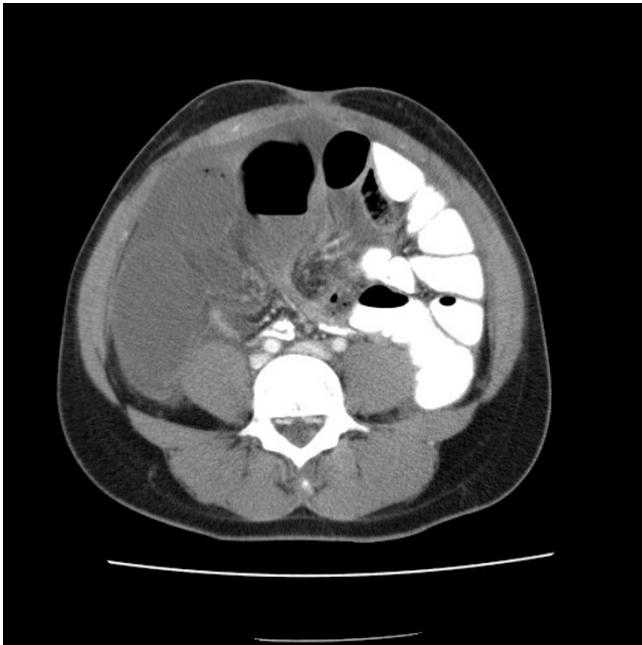

Figure 3
CT showing dilated proximal jejunum and a closed loop obstruction in the terminal ileum. There is a positive "swirl" sign consistent with a diagnosis of small bowel volvulus.

procedure include the development of cuff abscess, pouch leak, strictures, fistulation, stenosis, and pouchitis[16]. Small bowel obstruction as a complication of ileo-anal pouch formation has been described in the literature, and is usually a result of post-operative adhesions either within the pelvis, or at the site of the covering ileostomy[17-20]. The development of pouch ischaemia and

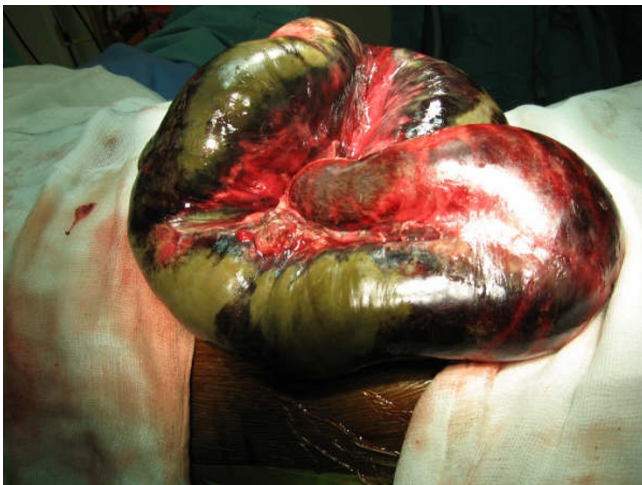

Figure 4
Intraoperative picture showing small bowel volvulus and necrotic bowel.

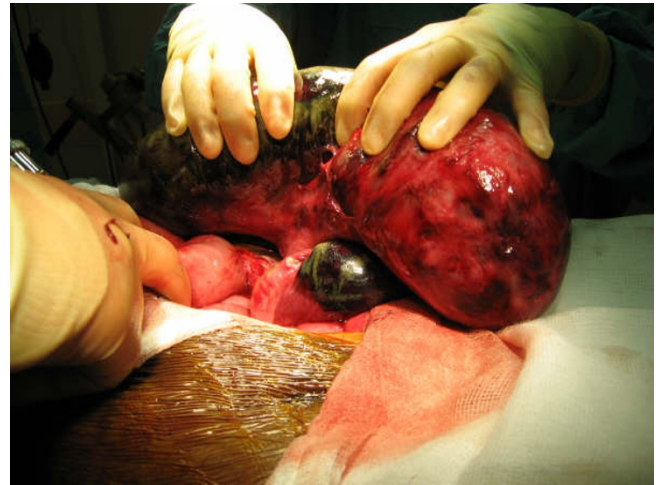

Figure 5
Intraoperative picture showing necrosis of ileo-anal pouch.

necrosis following small bowel volvulus however is a rare complication with only one reported case identified[10] with classical radiological 'corkscrew' findings as apparent in our case. This diagnosis should therefore be considered in patients presenting with small bowel obstruction following ileo-anal pouch procedures.

Consent

The patient concerned has given her full informed consent for the use of all radiology and pictures and the case history in the production of this paper

Competing interests

The authors declare that they have no competing interests.

Authors' contributions

SP drafted and edited the manuscript

GS drafted part of the manuscript

SG edited the manuscript

JH edited the manuscript

IA performed the surgery

BA performed the surgery

References

1. Iwuagwu O, Deans GT: **Small bowel volvulus: a review.** *J R Coll Surg Edinb* 1999/06/18 edition. 1999, **44(3)**:150-155.
2. Shimanuki Y, Aihara T, Takano H, Moritani T, Oguma E, Kuroki H, Shibata A, Nozawa K, Ohkawara K, Hirata A, Imaizumi S: **Clockwise whirlpool sign at color Doppler US: an objective and definite sign of midgut volvulus.** *Radiology* 1996/04/01 edition. 1996, **199(1)**:261-264.
3. Welch GH, Anderson JR: **Volvulus of the small intestine in adults.** *World J Surg* 1986/06/01 edition. 1986, **10(3)**:496-500.

4. Duke JH Jr., Yar MS: **Primary small bowel volvulus: cause and management.** *Arch Surg* 1977/06/01 edition. 1977, **112(6)**:685-688.
5. McDonald IO, Hawker DB: **Small bowel volvulus - the commonest abdominal emergency in Nepal.** *Bristol Med Chir J* 1980/01/01 edition. 1980, **95(355-356)**:4-8.
6. Vaez-Zadeh K, Dutz W, Nowrooz-Zadeh M: **Volvulus of the small intestine in adults: a study of predisposing factors.** *Ann Surg* 1969/02/01 edition. 1969, **169(2)**:265-271.
7. Chaussade S, Merite F, Hautefeuille M, Valleur P, Hautefeuille P, Couturier D: **Motility of the jejunum after proctocolectomy and ileal pouch anastomosis.** *Gut* 1989/03/01 edition. 1989, **30(3)**:371-375.
8. Freund H: **Volvulus of the small bowel in a diabetic patient.** *Br Med J* 1976/09/11 edition. 1976, **2(6036)**:641.
9. De Souza LJ: **Volvulus of the small bowel.** *Br Med J* 1976/05/01 edition. 1976, **1(6017)**:1055-1056.
10. Catalano O: **Small bowel volvulus following ileal pouch-anal anastomosis: CT demonstration.** *Eur J Radiol* 1996/09/01 edition. 1996, **23(2)**:115-117.
11. Khanna A, Newman B, Reyes J, Fung JJ, Todo S, Starzl TE: **Internal hernia and volvulus of the small bowel following liver transplantation.** *Transpl Int* 1997/01/01 edition. 1997, **10(2)**:133-136.
12. D'Souza CR, Kilam S, Prokopishyn H: **Axial volvulus of the small bowel caused by Meckel's diverticulum.** *Surgery* 1993/11/01 edition. 1993, **114(5)**:984-987.
13. Chou CK, Mark CW, Wu RH, Chang JM: **Large diverticulum and volvulus of the small bowel in adults.** *World J Surg* 2004/12/16 edition. 2005, **29(1)**:80-82.
14. Stout CL, Foret A, Christie DB, Mullis E: **Small bowel volvulus caused by migrating mesh plug.** *Am Surg* 2007/09/21 edition. 2007, **73(8)**:796-797.
15. Loh YH, Dunn GD: **Computed tomography features of small bowel volvulus.** *Australas Radiol* 2000/12/05 edition. 2000, **44(4)**:464-467.
16. Dayton MT, Larsen KR, Christiansen DD: **Similar functional results and complications after ileal pouch-anal anastomosis in patients with indeterminate vs ulcerative colitis.** *Arch Surg* 2002/06/07 edition. 2002, **137(6)**:690-4; discussion 694-5.
17. Aberg H, Pahlman L, Karlborn U: **Small-bowel obstruction after restorative proctocolectomy in patients with ulcerative colitis.** *Int J Colorectal Dis* 2006/11/15 edition. 2007, **22(6)**:637-642.
18. Marcello PW, Roberts PL, Schoetz DJ Jr., Collier JA, Murray JJ, Veidenheimer MC: **Obstruction after ileal pouch-anal anastomosis: a preventable complication?** *Dis Colon Rectum* 1993/12/01 edition. 1993, **36(12)**:1105-1111.
19. MacLean AR, Cohen Z, MacRae HM, O'Connor BI, Mukraj D, Kennedy ED, Parkes R, McLeod RS: **Risk of small bowel obstruction after the ileal pouch-anal anastomosis.** *Ann Surg* 2002/01/25 edition. 2002, **235(2)**:200-206.
20. Francois Y, Dozois RR, Kelly KA, Beart RW Jr., Wolff BG, Pemberton JH, Ilstrup DM: **Small intestinal obstruction complicating ileal pouch-anal anastomosis.** *Ann Surg* 1989/01/01 edition. 1989, **209(1)**:46-50.

Publish with **BioMed Central** and every scientist can read your work free of charge

"BioMed Central will be the most significant development for disseminating the results of biomedical research in our lifetime."

Sir Paul Nurse, Cancer Research UK

Your research papers will be:

- available free of charge to the entire biomedical community
- peer reviewed and published immediately upon acceptance
- cited in PubMed and archived on PubMed Central
- yours — you keep the copyright

Submit your manuscript here:
http://www.biomedcentral.com/info/publishing_adv.asp

